

# A DIAGNOSING CASE OF THE EYE AND ORBITAL TUMOR THROUGH B-SCAN

H. M. Noor ul Huda Khan Asghar<sup>c,1</sup>, H. M. Ajmal<sup>a</sup>, Mustansar Mahmood Waraich<sup>b</sup>, Zaheer Abbas Gilani<sup>c</sup>, Abdul Kareem Khan<sup>b</sup>, Jalil ur Rehman<sup>c</sup> and M. Afzal Khan<sup>a</sup>

<sup>a</sup>Department of Physics, Medical Physics lab, The Islamia University of Bahawalpur (IUB), Pakistan.

<sup>c</sup> Department of Physics, Balochistan University of Information Technology, Engineering & management Sciences (BUIITEMS), Quetta-Pakistan

<sup>b</sup>Department of Physics, Punjab College Bahawalpur, Pakistan

<sup>b</sup>Department of Radiology, Quaid-e-Azam Medical College Bahawalpur-Pakistan.

<sup>1</sup>noorulhudakhan@gmail.com

**Keywords:** A-Scan, B-Scan, morphology of the abnormality, Case series study

**ABSTRACT:** *The object was findings on B-scan in suspected cases of orbital masses. The method was case series studies at Bahawal Victoria Hospital Bahawalpur, Eye and Radiology Departments. 7.5 MHz linear probe was used on Closed Eyelids. Eye scanned by placing probe transversely and then longitudinally. Both eyes scanned thoroughly for comparison. 26 Male (52%) cases and 24 females (48%) cases were studied. Orbital inflammation and vascular tumors were diagnosed in 20% each. Cystic tumors were and Retinoblastoma were 12 % each. Melanoma and infiltrating malignant tumors were found 6 % each. Neurogenic tumors was 8%. Lacrimal Glands tumors, Grave disease and Osteoma were 4% 10% & 2% respectively. This study concluded that orbital masses could be diagnosed on B-scan with significant accuracy. Different diseases had different appearance on B-scan. B-Scan is a helpful tool in diagnosing orbital masses like vascular tumors, solid and cystic tumors, neurogenic tumors and inflammatory conditions.*

## INTRODUCTION

2-3 person per millions of population require orbital surgery for orbital tumors[1]. Incidence of orbital tumors is studied at different times Reese and Jones [2]. Studied 230 expanding lesion of orbit, among them 170 were orbital tumors [3].

Incidence of different orbital tumors in 170 consecutive orbital tumors was Hemangiomas[4], 28 (16.47%), Lymphosarcoma 22 (12.94%), Ch granuloma (Pseudo tumor) 18 (10.58%), Lacrimal gland epithelial 17 (10%), Meningiomas 11 (6.47%), Lymphangioma 10 (5.88%), Glioma of optic nerve 8 (4.70%), Metastatic malignant tumors 8 (4.70%), Peripheral nerve tumor 7 (4.12%), Dermoid cysts 7 (4.12%), Rhabdomyosarcoma 6 (3.53%), Angiosarcoma 5 (2.94%), Osteoma 5 (2.94%), Histocytoma 2 (1.18%).

In 1993 Yen Ko-Hsneh Pao published pathological classification of 435 consecutive primary orbital tumors [1], which were Mainly divided into eight groups like; Cystic lesions 83 (19.1%), Vasculogenic lesions 64 (15.1%), Mesenchymal tumors 50 (11.5%), Lacrimal gland tumors 73 (16.8%), Neural tissue tumors 54 (12.4%), Lymphatic lesion 55 (12.6%), Hystocytic lesion 16 (3.27%), Pseudo tumors 40 (9.2%), Difference in these two studies may be due to time duration, racial geographic or living condition.

The standardized A-scan was developed by Ossining for use in ophthalmology [5]. A-scan echography is a one dimensional acoustic display in which echoes are represented as vertical spikes from a baseline. Spacing of the spikes is dependent on the time required for the sound velocity of the medium from which the echoes are received. The height of the displayed spikes indicates the strength (i.e., amplitude) of the echoes [6]. The standardized A-scan requires the use of a non-focused 8 MHz transducer that emits a parallel sound

beam. External standardization is performed for each probe/instrument combination with a tissue model [7].

In B-mode, contrary to A-mode height of reflected wave is now squeezed down to a dot on the CRT display; its brightness will be proportional to the intensity of reflected wave, so this type of display is called brightness mode [6]. B-scan echography produces a two-dimensional acoustic section by using both the vertical and horizontal dimensions of the screen to indicate configuration and location. A section of tissue is examined by an oscillation transducer that emits a sound beam that "slices" through a tissue, much like slices with a knife.

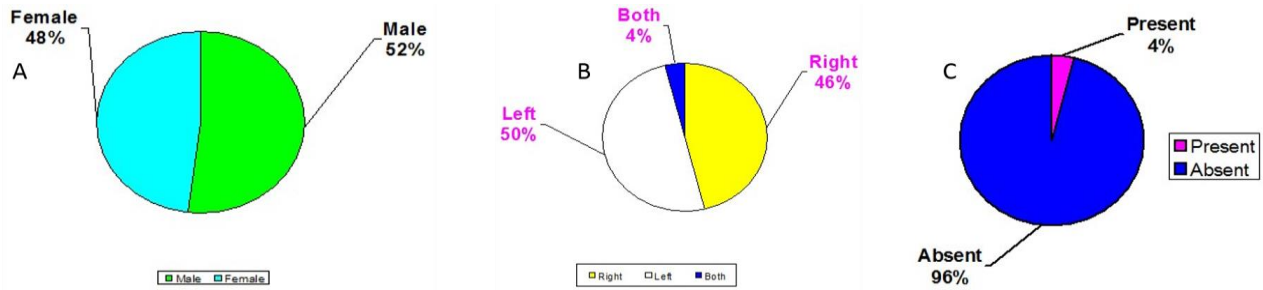
An echo is represented as a dot on the screen, using "Gray scale" processing, and the relative brightness of the dot is proportional to the amplitude of returning echo [8]. The coalescence of multiple dots on the screen forms a two-dimensional representation of the examined tissue section.

## EXPERIMENTAL AND RESULTS DISCUSSION

Study was carried in Radiology and Eye Departments of BVH Bahawalpur. 50 cases diagnosed with orbital masses on B-scan. 24 (48.0%) cases were females and 26 (52.0%) were males is shown in Figure 1 A

Left eye involved in half of cases (50%) while the right eye involvement was slightly less (46%). Both eyes were involved in 2 (4%) cases are shown in Figure 1 b . The difference was not statistically significant. Brain Extension noted in 2 (4%) cases, diagnosed on orbital and brain CT scan with contrast is shown in Figure 1 C

Patients Headache were present in 6 (12%) of cases, Redness of eye was found in 9 (18%) cases, 21 (42%) cases complained of pain in eye, Vision reduced was detected in 24 (48%) cases is shown in Figure 2, Discharging eye in 8 (16%) cases.

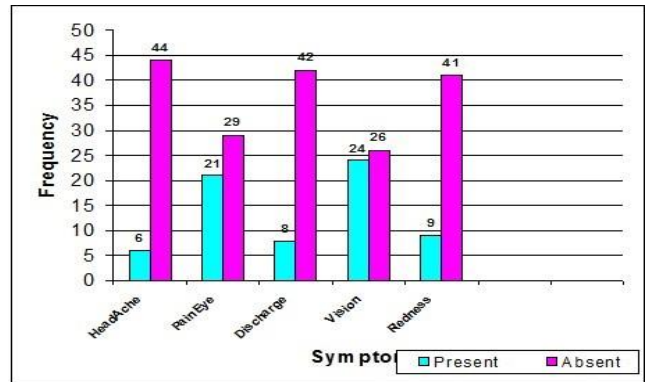


**Figure 1 (A) 50% was found in 1-20 years of age (B) Distribution of cases by side of eye involvements (C) Bony involvement seen in 4 % cases**

Orbital masses were observed in all ages ranging from 2 months to 65 years. The major proportion of cases (50%) was found in 1-20 years of age. (Table I). In study characterization of tumor types is as under: 10 cases Orbital Inflammation (Pseudotumor) 20 %, 10 cases vascular tumors 20 %, 6 cases Cystic tumors 12 %, 6 cases Retinoblastoma 12 %, 5 cases Graves Disease 10 %, 4 cases Neurogenic tumors 08 %, 2 cases Lacrimal Gland tumors 04 %, 1 cases Osteoma 02 %, 3 cases Infiltrating malignant tumors 06 %, 3 cases Malanoma 06 %.

**Table 1 (Distribution of cases by age) (n = 50)**

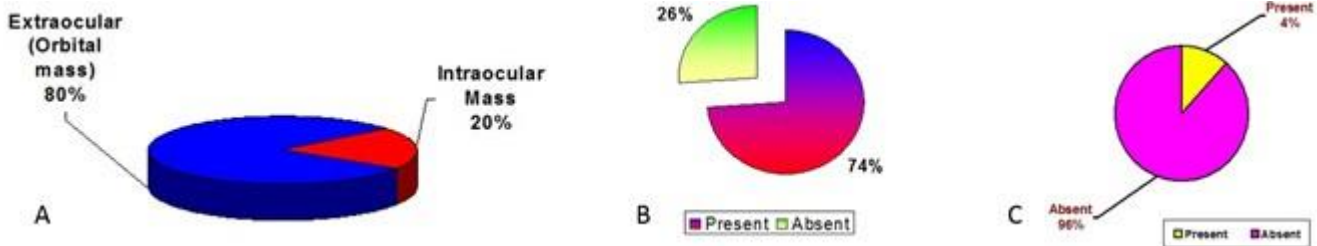
Age (years)	Frequency	Percentage%
< 1	1	02.0
1 – 10	15	30.0
11 – 20	10	20.0
21 – 30	8	16.0
31 – 40	6	12.0
41 – 50	7	14.0
51 – 60	2	04.0
> 60	1	02.0
Total	50	100



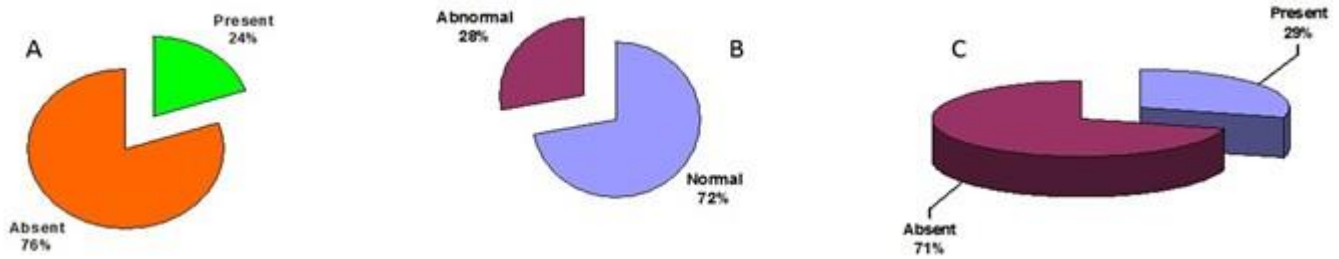
**Figure 2 Chief complaint**

Extraocular tumors were seen in forty (80%) cases while in ten (20%) cases tumors were intraocular as shown in Figure 3 A. Proptosis was seen in 13 (26%) cases and not seen in 37 (74%) cases as shown in Figure 3 B. Tumor Calcification Two (4%) cases of masses showed calcification and 48 (96%) of masses showed no calcification as shown in Figure 3 C.

Color Doppler Imaging Neovascularization in 12 (24%) cases. 38 (76%) of cases showing no abnormal flow in tumor mass as shown in Figure 4 A. Retrobulbar muscle abnormality seen in 14 (28%) cases and normal seen in 36(72%) as shown in Figure 4 B. Extraocular muscular involvement is 29% cases as shown in as shown in Figure 4 C.



**Figure 3 (A) Extra ocular & intraocular masses (B) Proptosis (C) Calcification**



**Figure 4 (A) Color Doppler Imaging Neovascularization 24%and 76% of cases showing no abnormal flow in tumor mass (B) Retro bulbar muscle abnormality 28% cases and normal 72% (C) Extraocular muscular involvement is 29%.**

The study was designed to diagnose eye and orbital tumor on B-Scan rather than A-Scan. The aim of study was to optimize sonographic visualization of eye in all Patients with suspected Eye problems and to find out whether sonography is useful in detection of Eye and Orbit disease. A-Scan is amplitude Scan which does not explains the morphology of the abnormality. But B-Scan is a Brightness mode real time scanning which tells about the size, outline and texture of the abnormality.

We can see the relation of abnormal focus from where it is arising and also what is its relation with normal organs. We can see that weather tumor or mass is cystic or solid, blood supply in it is decreased or increased & if any calcification is present in it that can easily be seen. It differentiates the nature of tumor. We can also decide that weather surgery will be beneficial or not. The object was findings on B-scan in suspected cases of orbital masses. The method was case series studies at Bahawal Victoria Hospital Bahawalpur (BVH), Eye and Radiology Departments. 7.5 MHz linear probe was used on Closed Eyelids. Eye scanned by placing probe transversely and then longitudinally.

Both eyes scanned thoroughly for comparison. 26 Male (52%) cases and 24 females (48%) cases were studied. Orbital inflammation was diagnosed in 10 cases (20%). Ten cases were found to be vascular tumors (20%). Cystic tumors were in six cases i.e. 12 % in this study. Retinoblastoma was in 6 cases 12 %. Three cases of melanoma (6 %) and three cases (6 %) diagnosed as infiltrating malignant tumors. 4 cases were neurogenic tumors (8%). Two cases were of Lacrimal Glands tumors (4%), 5 cases were Grave disease (10%) and 1 case was Osteoma (2%). Patients came with headache; red eye; discharging eye; painful eye; deterioration of vision or proptosis. Some of the complaints overlapped (Table II)

**Table 2 Distribution of cases by presenting complaints) n=75 Patients came with headache; red eye; discharging eye; painful eye; deterioration of vision or proptosis. Some of the complaints overlapped**

Complaints	Frequency	Percentage%
Headache	10	13.33
Painful eye	23	30.66
Discharge	12	16
Irritation	8	10.66
Redness	14	18.67
Fever	7	9.34
Vomiting	1	1.33
Total:	75	100

**CONCLUSION:**

This study concluded that orbital masses could be diagnosed on B-scan with significant accuracy. Different diseases had different appearance on B-scan. B-Scan is a helpful tool in diagnosing orbital masses like vascular tumors, solid and cystic tumors, neurogenic tumors and inflammatory conditions. Ophthalmic ultrasound (B-scan) findings are characteristic to diagnose different orbital masses. In Inflammatory lesions of the orbit, findings like enlarged extraocular muscles, optic nerve changes and T signs are present. The cystic shadows are indicative of cystic tumors, benign cyst or dermoid Cyst. Color Doppler B-scan shows arterial and venous flow in AV Fistula (vascular tumor). Neurogenic tumors have poor sound transmission. There is enlargement of muscles but no space-occupying lesion in Grave’s disease. In lacrimal gland tumors cystic or solid component in lacrimal sac can be depicted.

Retinoblastoma malignant tumor of eye commonly found in children has echogenic mass in vitreous showing calcification with or without retinal detachment. Increased color flow was also noted. Intraocular melanoma typical showed collar button appearance. Infiltrating malignant tumor has localized infiltration in globe. Retro bulbar region and optic nerve delineated on B-Scan with high resolution probe. For diagnosing distant metastasis in brain other modalities likely CT and MRI come into picture.

**ACKNOWLEDGEMENTS**

I acknowledge the Organization “MEDEQUIPS” Who provide me practically opportunity to do work on the Equipment to enhance the knowledge and data analysis.

**REFERENCES**

- 1 D. J. Coleman and F. L. Lizzi, *American journal of ophthalmology*, **96** (2), 165-175 (1983)
- 2 J. Németh, Á. Szabó, and M. Végh, *Acta Ophthalmologica* **70** (S204), 107-109(1992).
- 3 S. Byrne, *Ultrasound of the Eye and Orbit* Byrne SF, GreenRL. eds. London:. St Louis, 115-190(2002).
- 4 C. DiBernardo, E. M. Pacheco, J. R. Hughes, W. J. Iliff, and S. F. Byrne, *Ophthalmology* **103** (11), 1794-1797(1996).
- 5 K. C. Ossoinig, S. L. Frazier, R. C. Watzke, and J. G. Diamond, in *New and Controversial Aspects of Vitreoretinal Surgery*, CV Mosby St Louis, , pp. 106-125(1977).

- 6 W. J. Mackillop, Y. Zhou, and C. F. Quirt, 8 R. E. Sabbagha, *Diagnostic ultrasound applied to  
International Journal of Radiation Oncology\* obstetrics and gynecology.* (HarperCollins  
*Biology\* Physics* **32** (2), 531-539(1995). Publishers, 1980).
- 7 P. Till and K. Ossoinig, *Bibliotheca  
ophthalmologica: **supplementa ad**  
ophthalmologica* (83), 49-62(1974).